

Chronic central serous choroidopathy with severe visual loss in hyperopic microphthalmic identical twins

Abstract

Objective: To report chronic central serous choroidopathy with severe visual loss in hyperopic microphthalmic identical twins.

Methods: The index patient was first examined in 1994, at age 31, and has been followed up closely for 17 years. He had repeated fluorescein and indocyanine green angiograms, OCT, ultrasound biometry, and recently also autofluorescence and EDI OCT. His twin brother was first examined in 2010, at age 47, and had a similar extensive exploration.

Results: The index patient had a mean refractive error of +6 D OU and VA was 20/32++ in the RE and 20/200 in the LE in 1994. Vision slowly went down to 20/800+ in the RE and 20/600 in the LE in 2011. His twin brother has a mean refractive error of +6 D OU and VA 20/400 OU. Both have a short axial length of the eye, a thick choroid with dilated vessels, and central serous choroidopathy with cystic degeneration of the macula and retina in the posterior pole.

Conclusions: We add to the reported complications of microphthalmos, chronic central serous choroidopathy.

Keywords: identical twins, hyperopia, central serous choroidopathy, thick choroid, short ocular axial length, EDI OCT, ultrasound A-scan biometry, autofluorescence imaging, fluorescein and indocyanine green angiography, microphthalmos, posterior microphthalmos, nanophthalmos

Annelies Fabry¹
Johan Blanckaert¹
Anita Leys¹

¹ Department of
Ophthalmology, University
Hospitals Leuven, Leuven,
Belgium

Introduction

So far, hyperopia is not considered to be a risk factor for central serous choroidopathy (CSC). Twins with high hyperopia were reported by Black in 1924 [1] and CSC has been observed in identical twins by Jonkers in 1960 [2], but none had the combined pathology. Familial CSC [3] and familial chronic CSC [4] without hyperopia have been reported by others. We report CSC with severe visual loss in hyperopic identical twins. Ultrasound A-scan biometry showed reduced total total axial length of the globes, and EDI OCT showed dilated choroidal veins and a thick choroid. These findings show that hyperopia with short axial length of the eye can predispose to CSC [5], [6], [7], [8], [9], [10], [11], [12], [13], [14], [15], [16], [17], [18], [19], [20], [21], [22], [23].

Case presentation

Index patient

The index patient started wearing spectacles at age 14, when he was learning weaving techniques. For several years the hyperopic correction was increased, and the corrected VA allowed the patient to work easily. At age 27, vision loss was noticed, first in the left eye and later in the right eye. His ophthalmologist was unable to correct

the vision, diagnosed a maculopathy, and referred the patient to a medical retina specialist, who advised laser-coagulation. The patient did not want this treatment, waited for some time, and came to see us for second opinion in 1994, at age 31.

External examination of the eyes was normal, including corneal size (11 mm diameter OU) and palpebral fissure (Figure 1). BCVA was 20/32++ in the RE and 20/200 in the LE (correction RE sph +5.25 cyl +1.50 axis 42 and LE +5.50 cyl +0.75 axis 109). Ocular tension was 17 mmHg RE and 18 mmHg LE. Biomicroscopic examination showed in both eyes a mildly reduced anterior chamber depth and a maculopathy (Figure 2). Fluorescein angiography confirmed the presumed diagnosis of CSC OU with macular serous detachment, diffuse pigment epitheliopathy, and mild focal subretinal leakage (Figure 3). Focal lasercoagulation was performed in the RE in 1995, 1996, 1997 and 1998, but despite this treatment the macular detachment increased slowly and cystic retinal degeneration and fibrosis became evident, as well in the RE as in the LE (Figure 4). Repeated FA revealed progressively expanding subretinal lesions in the posterior pole of both eyes, with leakage, staining and pooling of fluid (Figure 5). In 2004, PDT was available, and as the exudative lesions were pronounced, one session of SFR PDT was administered in the LE, however, without benefit. Over the last years of follow-up eye drops with dorzolamide were used, apparently without benefit.



Figure 1: Index patient in 2011, at age 48, and his twin brother who looks almost exactly alike. Note normal palpebral fissures, normal size of the cornea and no deep set globes.

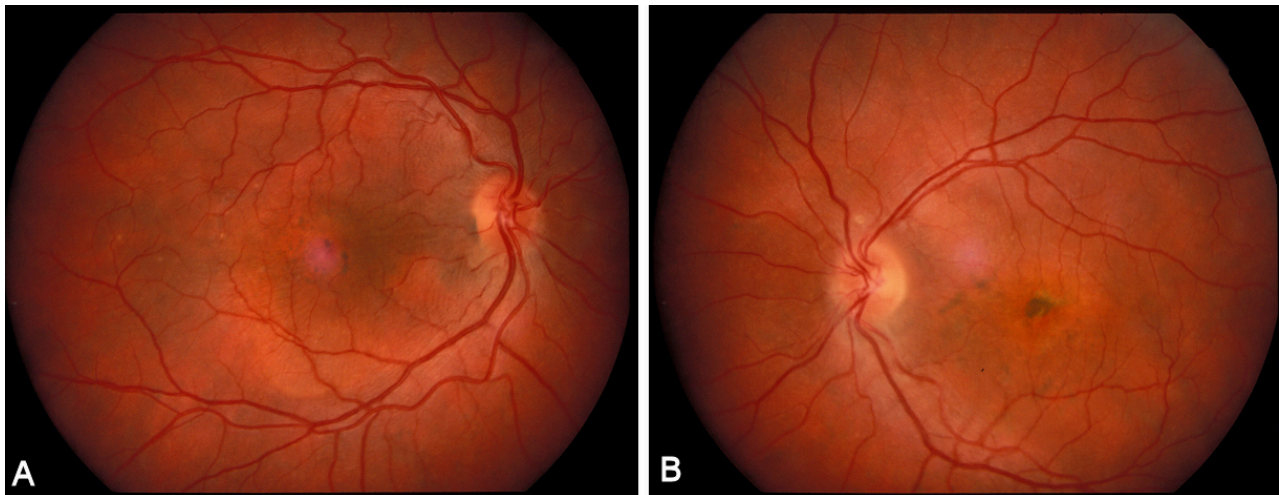


Figure 2: Index patient in 1994, at age 31. Colour photograph of the RE (A) and LE (B) showing a bilateral maculopathy with serous macular detachment.

OCT was available in 1997, and repeated scans showed pronounced and progressive cystic degeneration of the macula OU (Figure 6). EDI OCT, available in 2011, demonstrated dilated choroidal vessels and a thick choroid (Figure 7). ICGA also showed dilated choroidal vessels (Figure 8). Ultrasound A-scan biometry demonstrated OU reduced total axial length, reduced anterior chamber depth, reduced vitreous cavity and increased lens thickness (Table 1). Recently, atrophic changes became evident (Figure 9) and on OCT decreased retinal

thickness was observed (Figure 7). Autofluorescence imaging showed large areas of hypoautofluorescence compatible with afunctional retinal pigment epithelium and retina (Figure 10). VA in 2011 was 20/800+ in the RE and 20/600 in the LE.

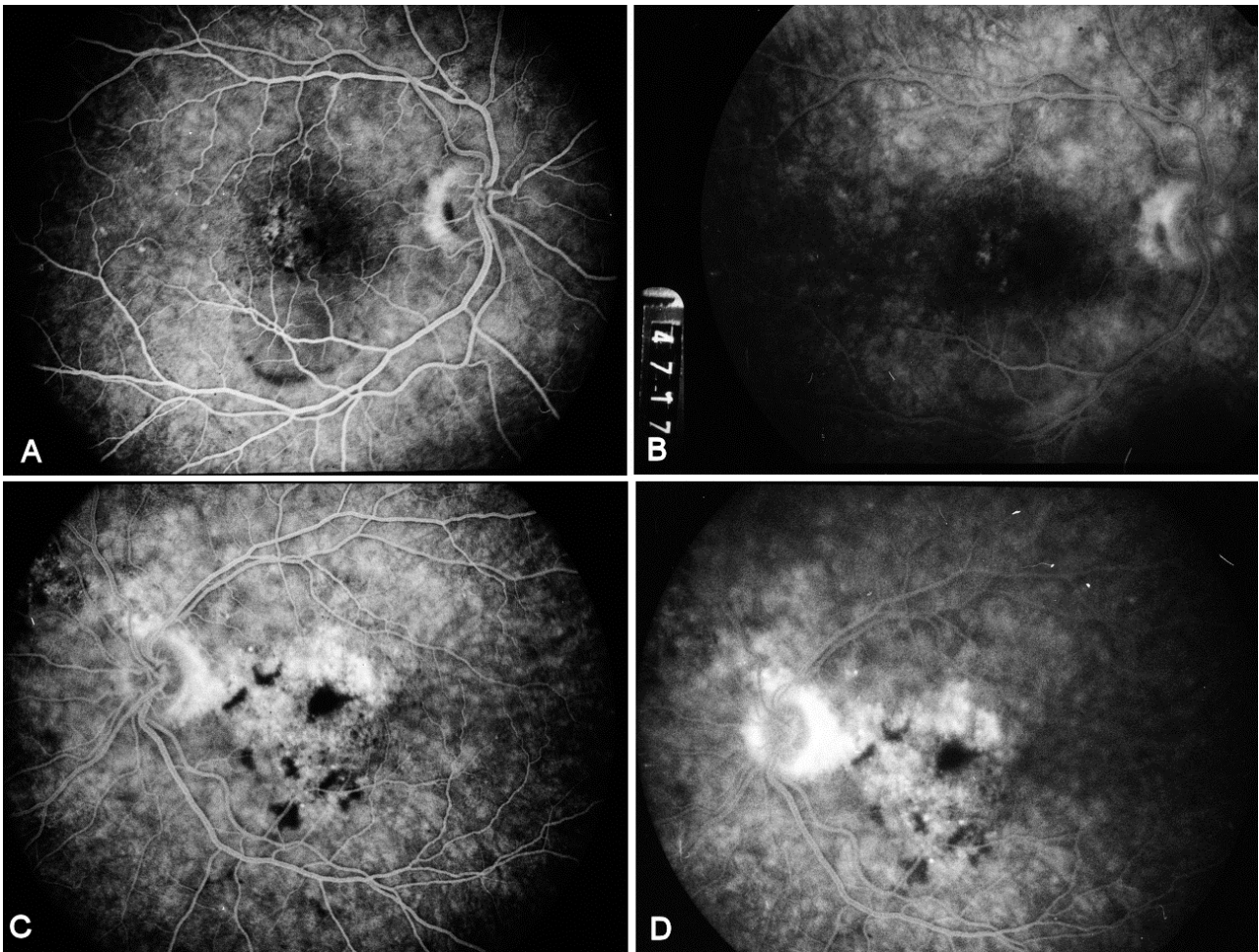


Figure 3: Index patient in 1994, at age 31. Fluorescein angiography of the RE, early phase (A) and late phase (B), and of the LE early phase (C) and late phase (D) show macular RPE window defects OU and mild subretinal focal leakage.

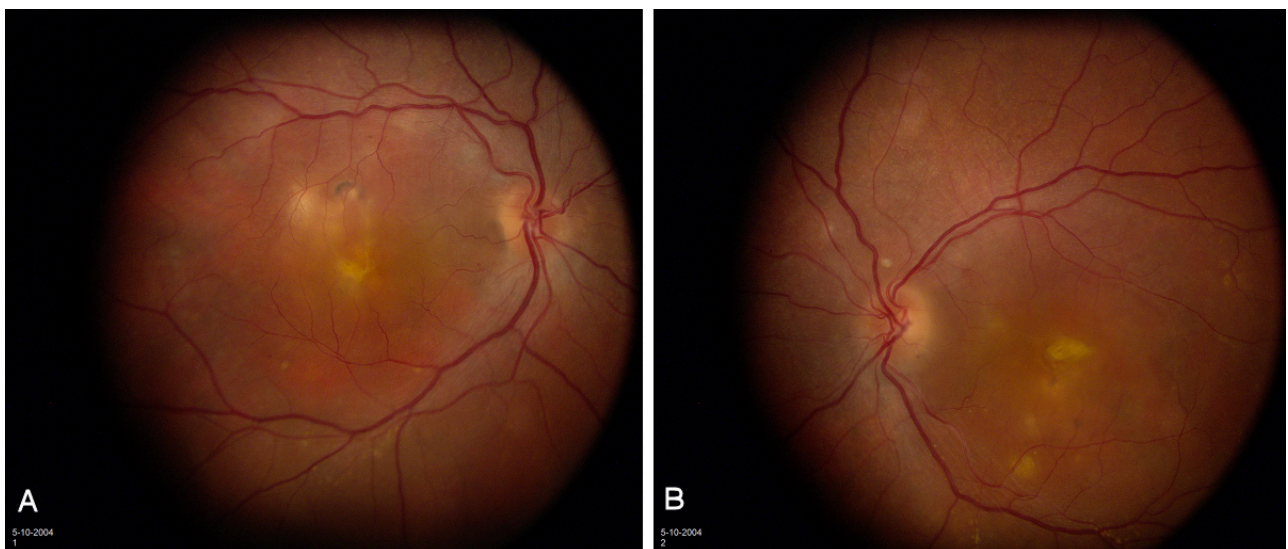


Figure 4: Index patient in 2004, at age 41. Note in the RE (A) and in the LE (B) pronounced serous elevation of the macula, cystic degeneration of the retina and fibrotic changes.

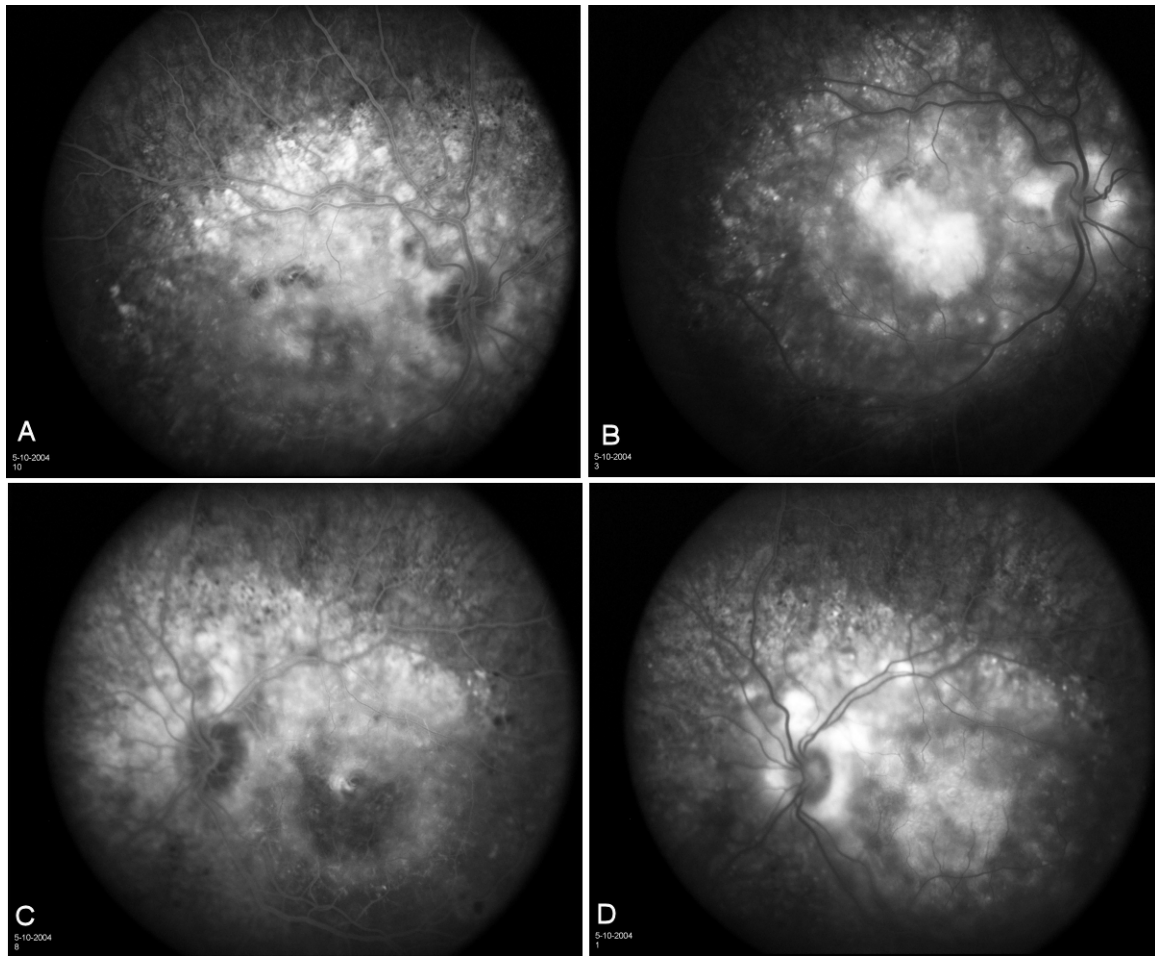


Figure 5: Index patient in 2004, at age 41. Fluorescein angiography AV filling phase of the RE (A) and LE (B) and late phase in the RE (C) and LE (D) show large lesions with RPE window defects, leakage staining and pooling of dye.

	Index RE	Index LE	Brother RE	Brother LE	Isolated simple microphthalmos	Posterior microphthalmos	Posterior microphthalmos	Emmetropic subjects	Emmetropic subjects
					range	range (mm)	mean value (mm)	mean value (mm)	standard deviation (mm)
Corneal diameter	11	11	11	11	10–11.5	10.5–12	11.5	11.3	0.4
Anterior chamber depth	2.12	2.25	2.02	2.03	Normal in most patients	2.8–3.7	3.2	2.9	0.3
Lens thickness	5.27	5.07	5.26	5.22	NA	3.7–4.5	4.1	4.3	0.3
Axial vitreous cavity length	12.22	12.34	12.41	12.50	>2 SD below mean	7.0–11.2	8.7	15.3	0.7
Total axial length	19.61	19.66	19.70	19.76	17–20.8	14.8–18.3	16.0	23.4	0.75
Mean refractive error (diopter)	+7	+7	+7	+7	+6.75–+11	+12–+19	NA	0	0

Table 1: Biometric data and mean refractive error in the twin brothers compared to emmetropic subjects (Delmarcelle et al. 1976 [24]), patients with isolated simple microphthalmos (Weiss et al. 1989 [9]), and patients with posterior microphthalmos (Khairallah et al. 2002 [16]).

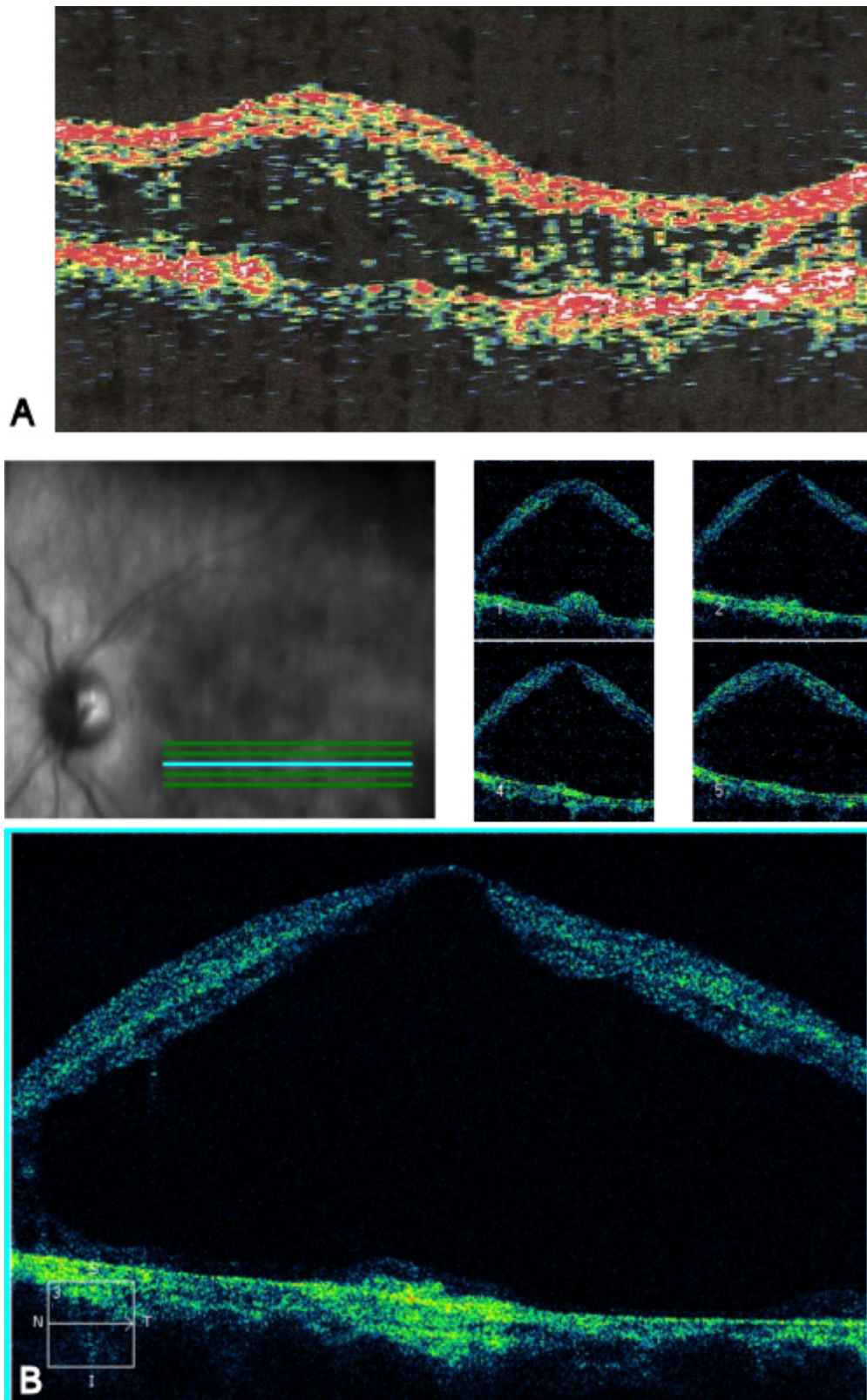


Figure 6: Index patient, LE. OCT Stratus in 1999, at age 36 (A) and OCT Stratus in 2007, at age 44, show progressive and pronounced cystic degeneration of the macula.

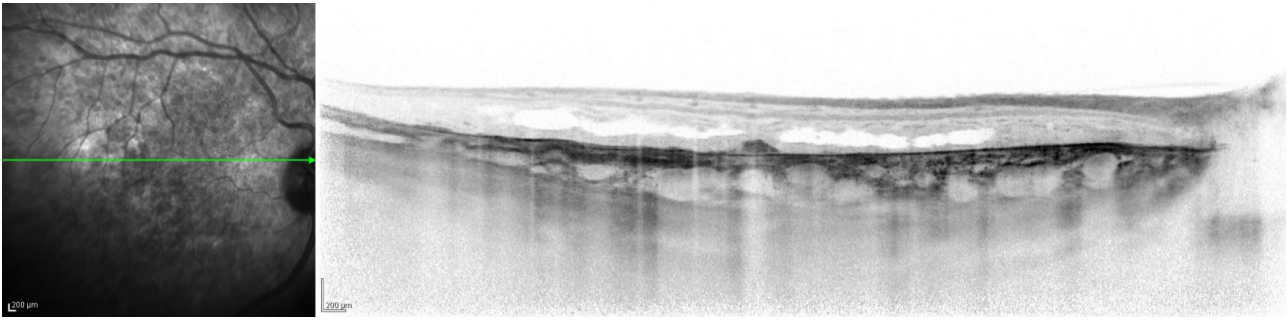


Figure 7: Index patient, OCT Spectralis EDI in 2011, at age 48. Note dilated choroidal vessels and a thick choroid, and cystic degeneration of the retina, with reduced thickness of the retina compared to previous recordings.

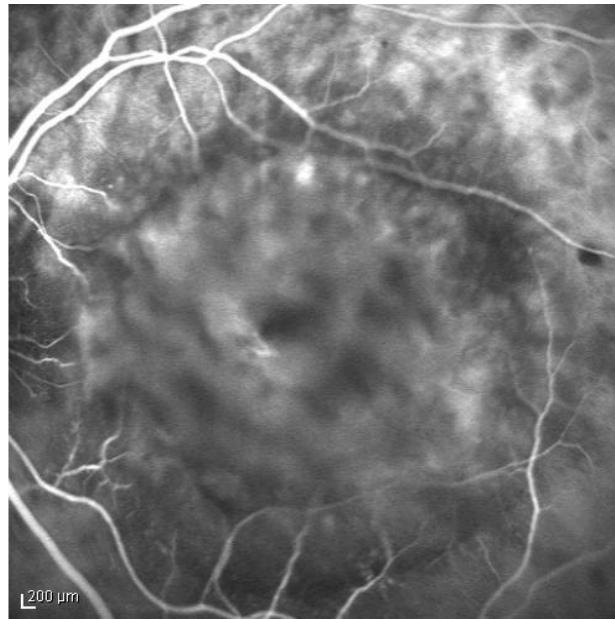


Figure 8: Index patient, ICGA in 2004, at age 41. Note dilated choroidal vessels in the left eye.

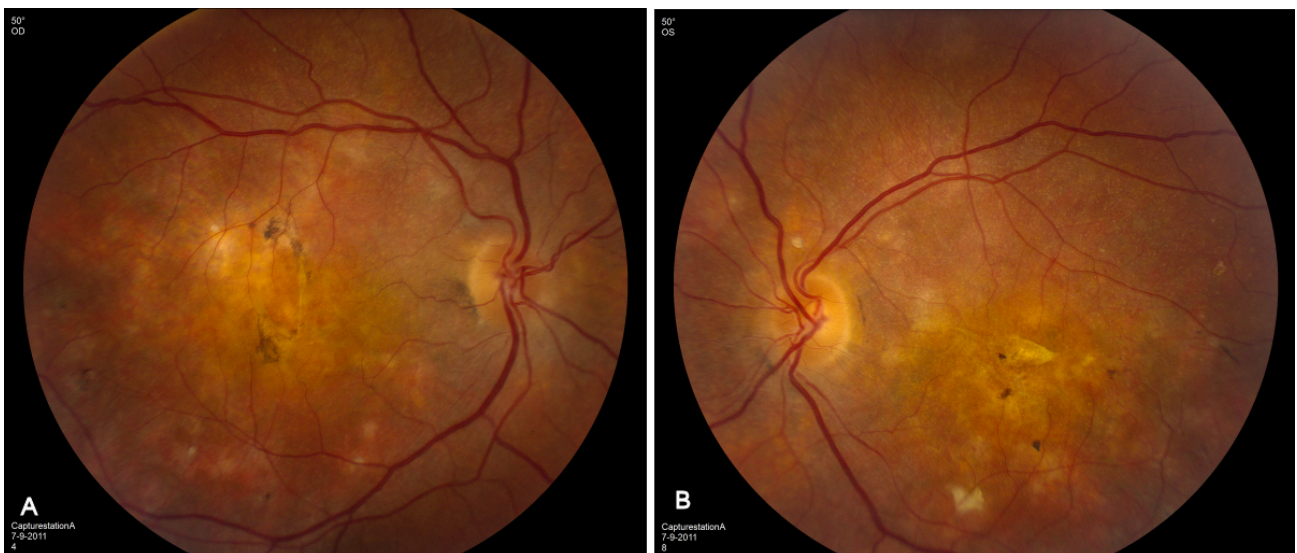

Figure 9: Index patient in 2011, at age 48. Widespread atrophic and degenerative changes are noted in the posterior pole of the RE (A) and left eye (B).

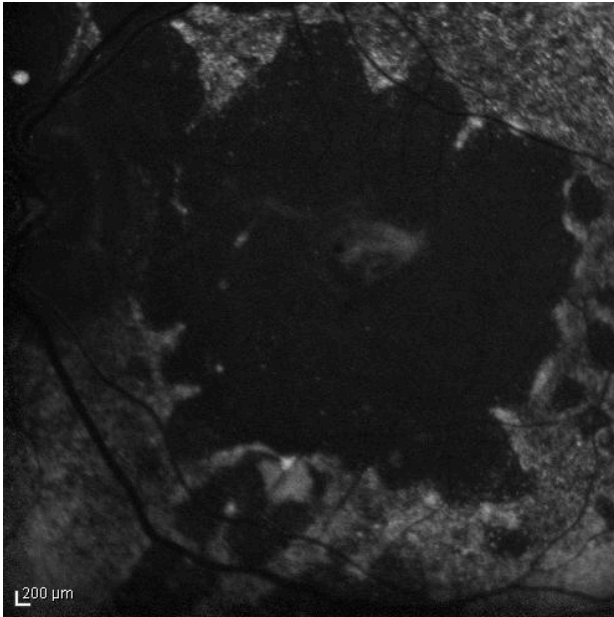


Figure 10: Index patient in 2011, at age 48. Autofluorescence imaging of the LE shows large areas of hypoautofluorescence compatible with atrophy and afunctional retinal pigment epithelium and retina.

Twin brother

The twin brother received his first pair of glazes at age 21. He is working as a gardener without major visual problems, but at age 34 developed reading problems and vision loss. At age 47, he realized to have a similar eye problem as his twin brother, and consulted for diagnosis and testing of low vision aids. External examination of the eyes was normal, including corneal size (diameter 11 mm OU) and palpebral fissures (Figure 1). BCVA was 20/400 OU (RE sph +6.25 cyl -0.75 axis 113° and LE sph 7.00 cyl -1.75 axis 67°). Ocular pressure was normal (16 and 15 mmHg on pneumotonometry). Biomicroscopic examination showed a mildly reduced anterior chamber depth and a bilateral maculopathy with CSC very similar to his brothers. Autofluorescence imaging (Figure 11), fluorescein angiography (Figure 12) and indocyanine green angiography (Figure 13), OCT and EDI-OCT (Figure 14), and ultrasound biometry (Table 1) were performed and showed similar ocular anomalies and a maculopathy that was slightly milder than his brother's. Over the next year the maculopathy got slightly worse (Figure 15).

Discussion

The twins reported in this paper are 6 diopters hyperopic in both eyes, have normal corneal size, and presented with bilateral chronic central serous choroidopathy and severe visual loss. The four eyes have similar biometric ocular data with mildly reduced anterior chamber depth, a lens thicker than expected, reduced vitreous cavity and reduced total axial length. These data confirm a develop-

mental anomaly in the spectrum of microphthalmos [24] (Table 1).

Microphthalmos is a congenital ocular malformation with reduced size of the globe. The clinical suspicion can be raised on the basis of apparently small eyes [25]. In suspected patients another condition, blepharophimosis, should be excluded. Blepharophimosis is characterized by small palpebral fissures, but normal size of the globe [25].

Microphthalmos can present as an isolated ocular anomaly (isolated simple or pure microphthalmos), or in association with other ocular or systemic abnormalities. The spectrum of associated anomalies is broad, and includes coloboma, mental retardation, neurologic and renal anomalies, fetal alcohol syndrome, myotonic dystrophy and achondroplasia [9], [26], [27]. Both autosomal dominant and recessive forms of inheritance have been reported in microphthalmos. According to Warburg [25], [26], there are more than 130 syndromes which may present microphthalmos and over 70 with blepharophimosis, but in only 13 cases are the two found in the same syndrome. So far, the molecular genetics of the morphogenesis of the eye and, thus of microphthalmos, have revealed that PAX6 at 11p13, PAX3 at 2q35, and the microphthalmia transcription factor MITF are of importance for the embryonic growth of the eye, but blepharophimosis has not been reported in patients with mutations or deletions of these genes [25]. We have reported microphthalmos in a patient with renal-coloboma syndrome associated with PAX2 mutation [27]. Sundin et al. [19] have shown that recessive nanophthalmos is caused by severe mutations in the MFRP gene at 11q23.3. This gene encodes the Frizzled-related transmembrane protein MFRP that is selectively expressed in the retinal pigment epithelium (RPE) and ciliary body. MFRP protein is required for both prenatal ocular growth and postnatal emmetropization. Othman et al., reported autosomal dominant nanophthalmos (NNO1) with high hyperopia and angle-closure glaucoma mapping to chromosome 11 [14].

Whenever a patient is suspected of having microphthalmos, an ultrasound determination of the axial length of the eye should be provided [25]. Ultrasound biometry allows accurate assessment of the total axial length of the globe, the anterior chamber depth and risk for angle closure glaucoma [14], [18], and the volume of lens and vitreous cavity. Based on biometric data harmonious microphthalmos is differentiated of posterior microphthalmos. Microphthalmos can be extreme with blindness [27] or relatively mild with spared vision [9].

Posterior microphthalmos disproportionately affects the posterior ocular segment with normal external appearance of the eyes [6]. The corneal size and the anterior segment dimensions are normal, but there is foreshortening of the posterior ocular segment and high hyperopia. This hyperopia and an elevated papillomacular retinal fold are the main causes of visual impairment [6], [12], [13], [16], [17], [21]. A disparity in growth between the

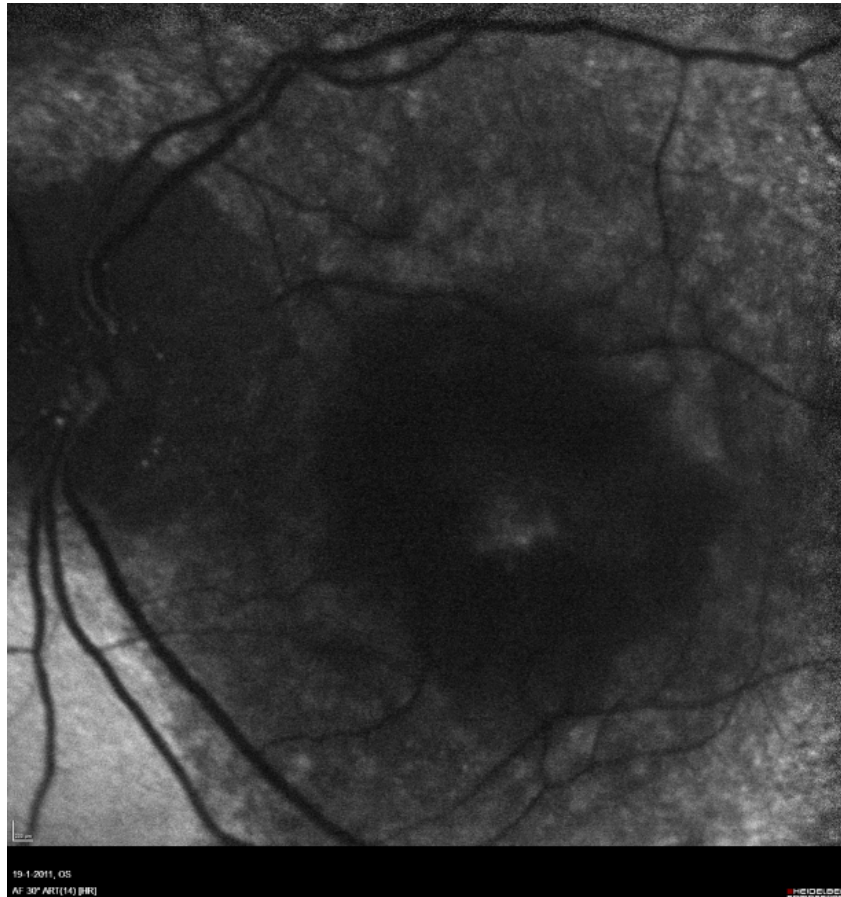


Figure 11: Twin brother in 2010, at age 47. Autofluorescence imaging of the LE shows similar, but less pronounced than in the index patient, large areas of hypoautofluorescence compatible with atrophy and afunctional retinal pigment epithelium and retina.

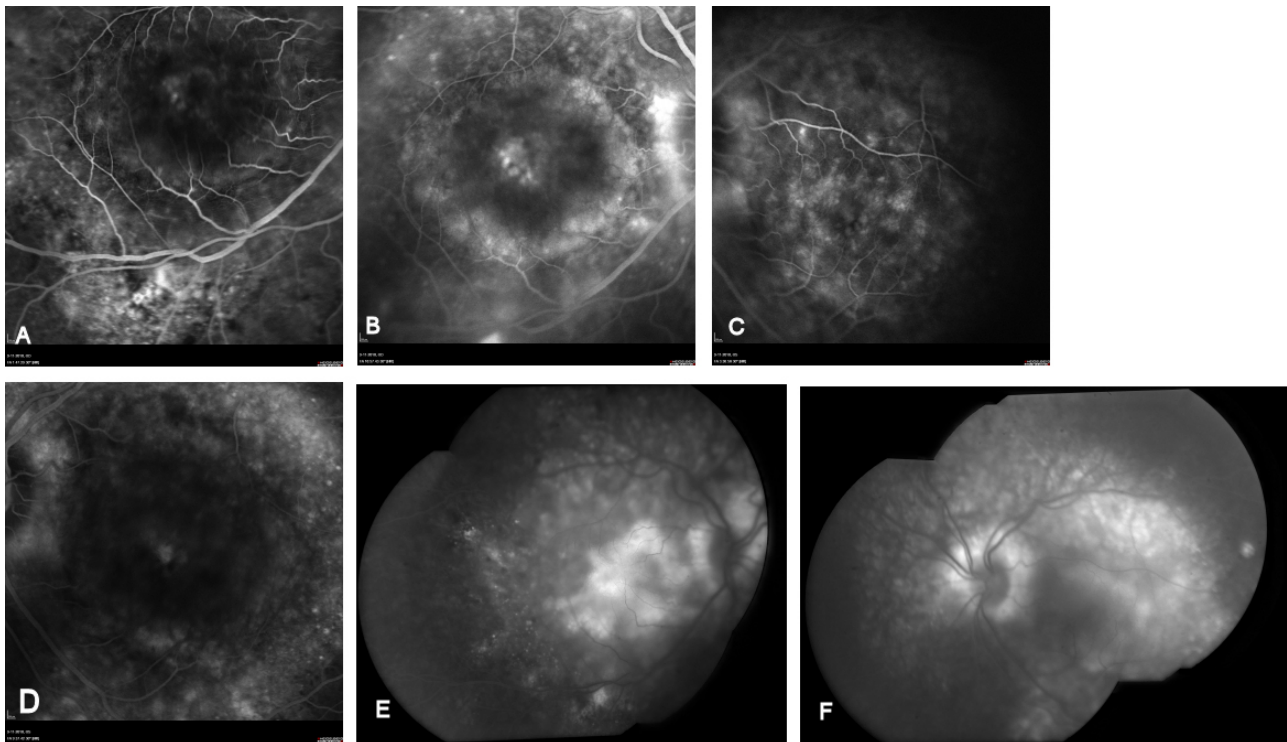


Figure 12: Twin brother in 2010, at age 47. HRA fluorescein angiography of the RE and LE in AV phase and at 10 minutes (A-D) and OIS composite image at 16 minutes show bilateral cystic elevation of the macula, RPE window defects, leakage and late pooling, similar to the FA changes in the index patient.

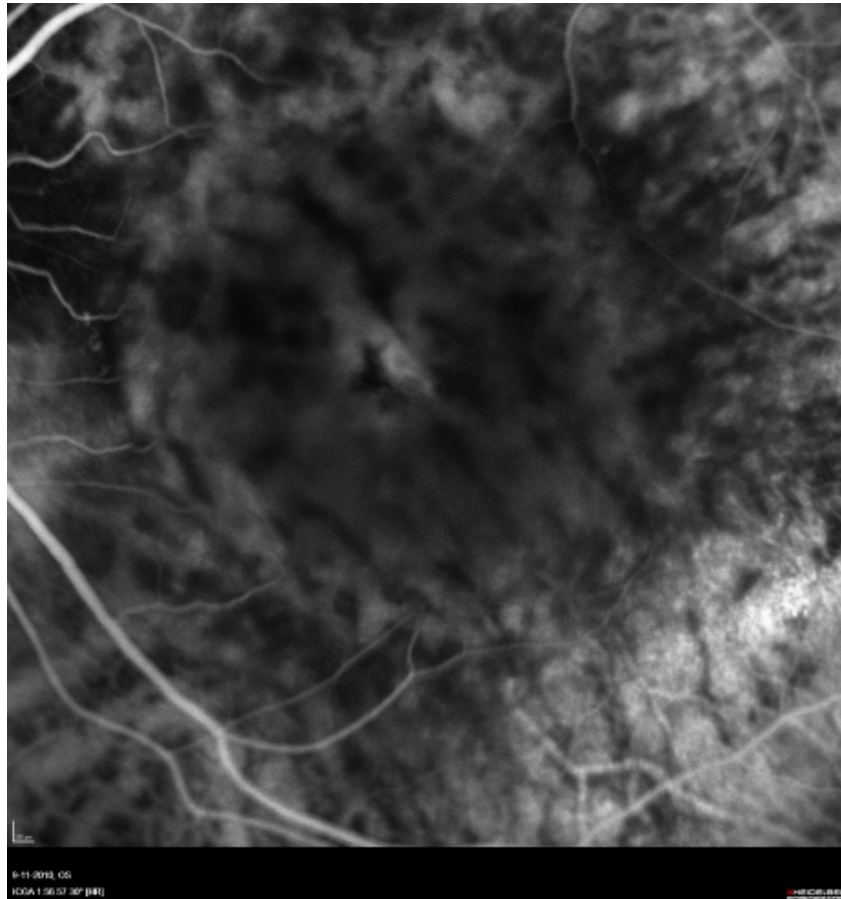


Figure 13: Twin brother in 2010, at age 47. ICGA in 2010, at age 46. Note dilated choroidal vessels in the left eye similar to the changes in the index patient.

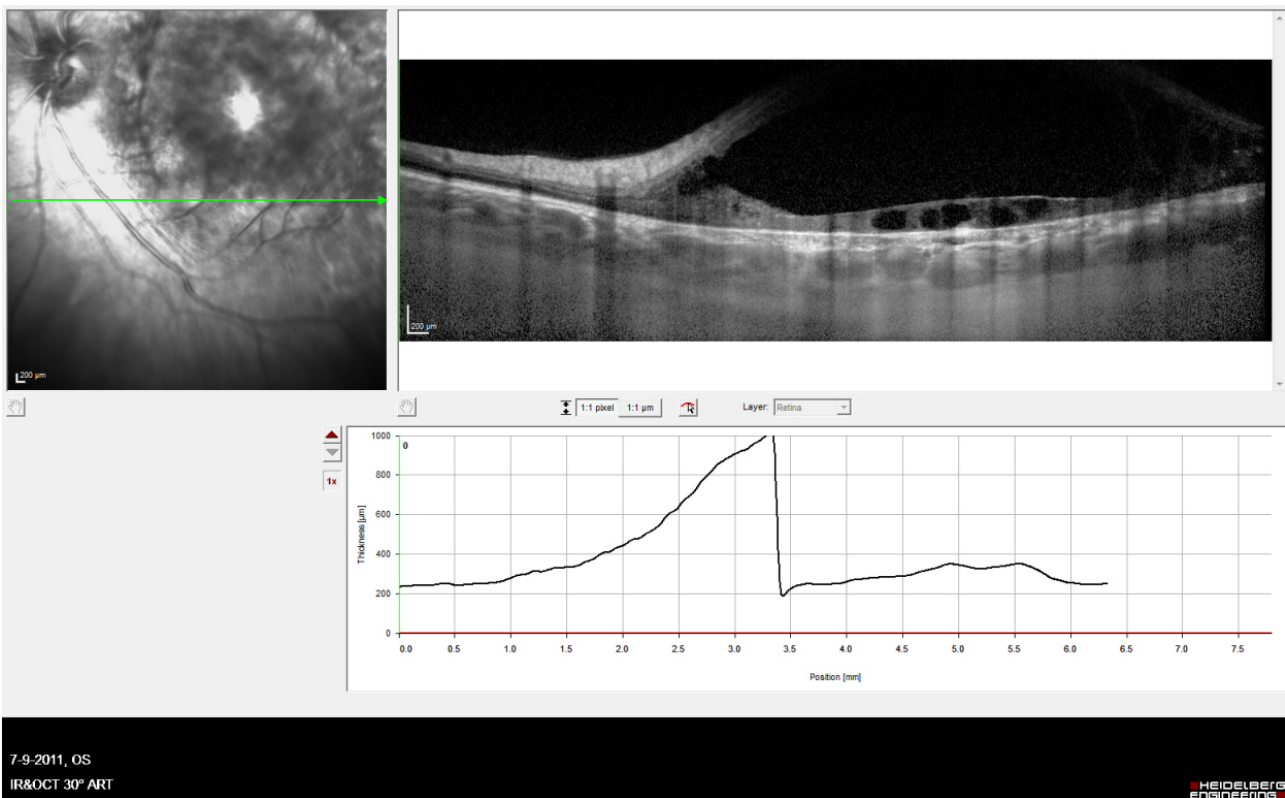


Figure 14: Twin brother in 2010, at age 47. OCT Spectralis EDI of the LE shows dilated choroidal vessels and a thick choroid and cystic degeneration of the retina.

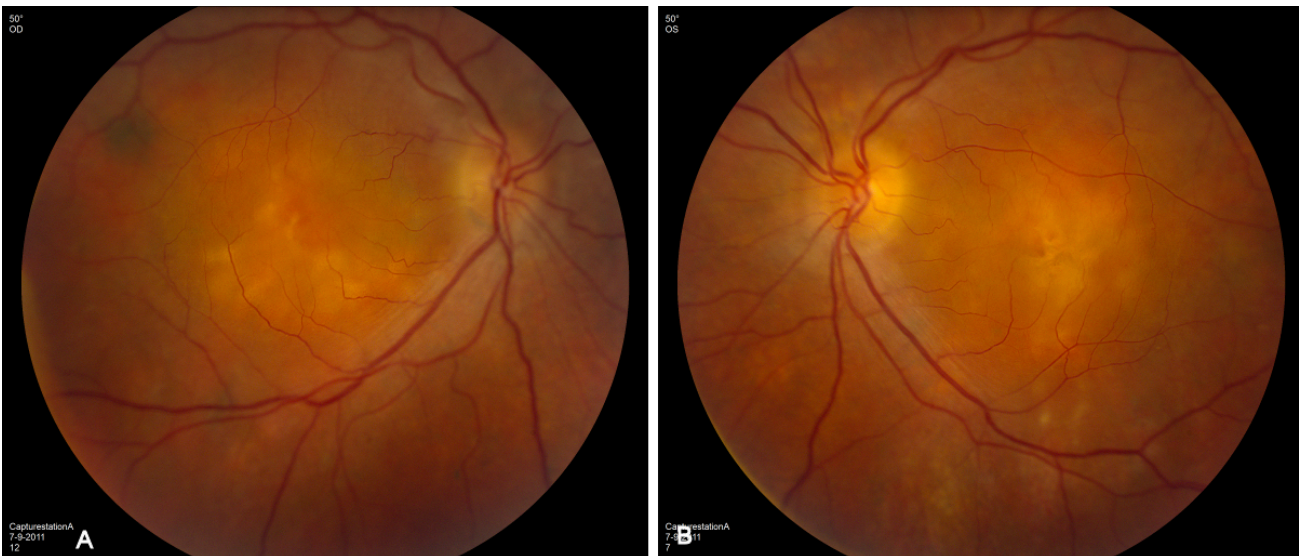

Figure 15: Twin brother in 2011, at age 48. Note in the RE (A) and in the LE (B) pronounced serous elevation of the macula, cystic degeneration of the retina and fibrotic changes, very similar to the changes observed in his brother.

sclera and retina probably gives rise to the frequently identified elevated papillomacular retinal fold [6], [16]. Other relatively frequent ocular abnormalities observed in microphthalmos/posterior microphthalmos are absence of the capillary-free zone, retinal striae, chorioretinal folds, uveal effusion, pigmentary retinal dystrophy and pseudopapilledema [13], [16], [17]. Macular hole, retinitis punctata albescens, and acquired retinoschisis [20] have been reported as a rare association.

The terminology of nanophthalmos has been used mainly in poorly defined phenotypes with small eyes, thick sclera and uveal effusion [5], [7], [8], [15], [23]. The thickened sclera impedes vortex venous drainage and/or reduces transscleral flow of protein from the eye, which causes fluid accumulation (from the choriocapillaris) in the choroid, subretinal space, or both. This may produce choroidal congestion, choroidal detachment, and/or exudative retinal detachment.

The twins reported in this paper have biometric data with reduced total axial length. Their data (Table 1) only mildly differ from those reported by Weiss et al. in 1989 in a study of 10 patients with isolated simple microphthalmos [9] and from those reported by Khairallah et al. in 2002 in a study of 18 patients with posterior microphthalmos [16]. We conclude that high hyperopia urges the ophthalmologist to perform ultrasound biometry to confirm or exclude microphthalmos. Eyes with reduced axial length are microphthalmic and require additional investigation to detect associated anomalies and follow up should be proposed as there is a risk of treatable complications. A shallow anterior angle implies a risk of angle closure glaucoma [7], [18], a treatable condition. Uveal effusion is another treatable complication of microphthalmos [8]. We add to the reported complications of microphthalmos, chronic central serous choroidopathy. Although we failed to stabilize vision, new therapies may become available in the next future making this complication treatable.

Notes

The authors have no notes/conflict of interest concerning the report of this case.

References

- Black M. Twins with high hyperopia. *Am J Ophthalmol.* 1924;7:375-6.
- Jonkers GH. Central serous retinopathy in a monozygotic twin-pair. *Acta Genet Metabol Gemelli.* 1960;IX:438-41.
- Lin E, Arrigg PG, Kim RY. Familial central serous choroidopathy. *Graefes Arch Clin Exp Ophthalmol.* 2000;238:930-1. DOI: 10.1007/s004179900110
- Weeninck AC, Borsje RA, Oosterhuis JA, et al. Familial chronic central serous chorioretinopathy. *Ophthalmologica.* 2001;215:183-7. DOI: 10.1159/000050855
- Brockhurst RJ. Nanophthalmos with uveal effusion. A new clinical entity. *Arch Ophthalmol.* 1975;93(12):1989-99.
- Spitznas M, Gerke E, Bateman JB. Hereditary posterior microphthalmos with papillomacular fold and high hyperopia. *Arch Ophthalmol.* 1983;101(3):413-7.
- Ghose S, Sachdev MS, Kumar H. Bilateral nanophthalmos, pigmentary retinal dystrophy, and angle closure glaucoma – a new syndrome? *Br J Ophthalmol.* 1985;69:624-8. DOI: 10.1136/bjo.69.8.624
- Allen KM, Meyers SM, Zegarra H. Nanophthalmic uveal effusion. *Retina.* 1988;8(2):145-7. DOI: 10.1097/00006982-198808020-00012
- Weiss AH, Kousseff BG, Ross EA, Longbottom J. Simple microphthalmos. *Arch Ophthalmol.* 1989;107(11):1625-30.
- Vingolo EM, Steindl K, Forte R, Zompatori L, Iannaccone A, Sciarra A, Del Porto G, Pannarale MR. Autosomal dominant simple microphthalmos. *J Med Genet.* 1994;31(9):721-5. DOI: 10.1136/jmg.31.9.721
- Neelakantan A, Venkataramkrishnan P, Rao BS, Krishnan N, Vijaya L, John S, Kar B. Familial nanophthalmos: management and complications. *Indian J Ophthalmol.* 1994;42(3):139-43.

12. Kida Y, Kurome H, Hayasaka S. Bilateral microphthalmos with poor visual acuity, high hyperopia, and papillomacular retinal folds in siblings. *Jpn J Ophthalmol*. 1995;39(2):177-9.
13. Serrano JC, Hodgkins PR, Taylor DS, Gole GA, Kriss A. The nanophthalmic macula. *Br J Ophthalmol*. 1998;82(3):276-9. DOI: 10.1136/bjo.82.3.276
14. Othman MI, Sullivan SA, Skuta GL, Cockrell DA, Stringham HM, Downs CA, Fornés A, Mick A, Boehnke M, Vollrath D, Richards JE. Autosomal dominant nanophthalmos (NNO1) with high hyperopia and angle-closure glaucoma maps to chromosome 11. *Am J Hum Genet*. 1998;63(5):1411-8. DOI: 10.1086/302113
15. Yamani A, Wood I, Sugino I, Wanner M, Zarbin MA. Abnormal collagen fibrils in nanophthalmos: a clinical and histologic study. *Am J Ophthalmol*. 1999;127(1):106-8. DOI: 10.1016/S0002-9394(98)00302-X
16. Khairallah M, Messaoud R, Zaouali S, et al. Posterior segment changes associated with posterior microphthalmos. *Ophthalmology*. 2002;109:569-74. DOI: 10.1016/S0161-6420(01)00996-4
17. Khan AO. Recognizing posterior microphthalmos. *Ophthalmology*. 2006;113:718. DOI: 10.1016/j.ophtha.2006.01.013
18. Bron A. Surgical indications in nanophthalmos. *J Fr Ophtalmol*. 2007;30(2):186-8. DOI: 10.1016/S0181-5512(07)89574-X
19. Sundin OH, Dharmaraj S, Bhutto IA, Hasegawa T, McLeod DS, Merges CA, Silval ED, Maumenee IH, Luttly GA. Developmental basis of nanophthalmos: MFRP is required for both prenatal ocular growth and postnatal emmetropization. *Ophthalmic Genet*. 2008;29(1):1-9. DOI: 10.1080/13816810701651241
20. Dhrami-Gavazi E, Schiff WM, Barile GR. Nanophthalmos and acquired retinoschisis. *Am J Ophthalmol*. 2009;147(1):108-10. DOI: 10.1016/j.ajo.2008.07.045
21. Khan AO. Posterior microphthalmos versus nanophthalmos. *Ophthalmic Genet*. 2008;29(4):189. DOI: 10.1080/13816810802258862
22. Khan A, Zafar SN. Variable retinal presentations in nanophthalmos. *J Pak Med Assoc*. 2009;59(11):791-3.
23. Moradian S, Kanani A, Esfandiari H. Nanophthalmos. *Journal of ophthalmic and vision research*. 2011;6(2):145-6. Available from: <http://www.jovr.ir/index.php/jovr/article/viewFile/298/323>
24. Delmarcelle Y, François J, Goes F, et al. Biométrie oculaire clinique (oculométrie). *Bull Soc belge Ophthalmol*. 1976;172:1-331.
25. Warburg M. Letter to the editor. Small eyes: descriptive misconceptions. *Am J Med Genetics*. 1995;59:388-9. DOI: 10.1002/ajmg.1320590322
26. Warburg M. Genetics of microphthalmos. *Int Ophthalmol*. 1981;4:45-65. DOI: 10.1007/BF00139580
27. Schimmenti LA, Cunliffe HE, McNoe LA, Ward TA, et al. Further delineation of renal-coloboma syndrome in patients with extreme variability of phenotype and identical PAX2 mutations. *Am J Hum Genet*. 1997;60(4):869-78.

Corresponding author:

Anita Leys

Department of Ophthalmology, University Hospitals
Leuven, Kapucijnenvoer 33, 3000 Leuven, Belgium
anita.leys@uzleuven.be

Please cite as

Fabry A, Blanckaert J, Leys A. Chronic central serous choroidopathy with severe visual loss in hyperopic microphthalmic identical twins. *GMS Ophthalmol Cases*. 2011;1:Doc05.
DOI: 10.3205/oc000005, URN: urn:nbn:de:0183-oc0000055

This article is freely available from

<http://www.egms.de/en/journals/oc/2011-1/oc000005.shtml>

Published: 2011-11-07

Copyright

©2011 Fabry et al. This is an Open Access article distributed under the terms of the Creative Commons Attribution License (<http://creativecommons.org/licenses/by-nc-nd/3.0/deed.en>). You are free: to Share — to copy, distribute and transmit the work, provided the original author and source are credited.