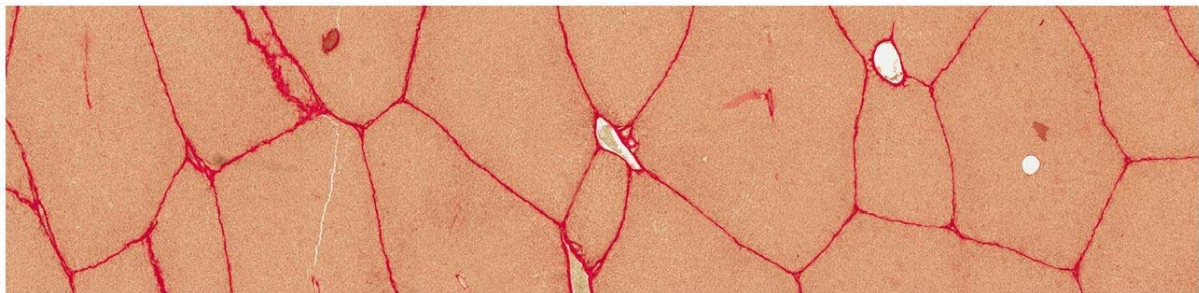


Attachment 1: Development of the software “Histologie für Mediziner” for medical histology courses: Sample learning unit

A

LEBER, GALLENBLASE, PANKREAS



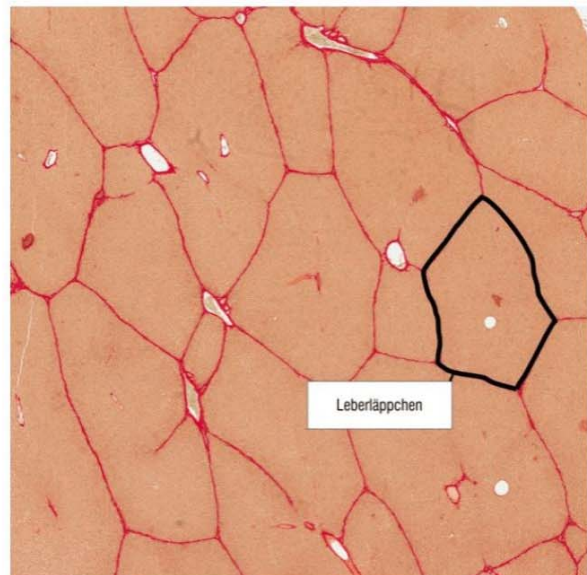
Kapitel 1: Leber (Schwein) – van Gieson



B



Leber (Schwein) – Aufbau des klassischen Leberläppchens
– van Gieson

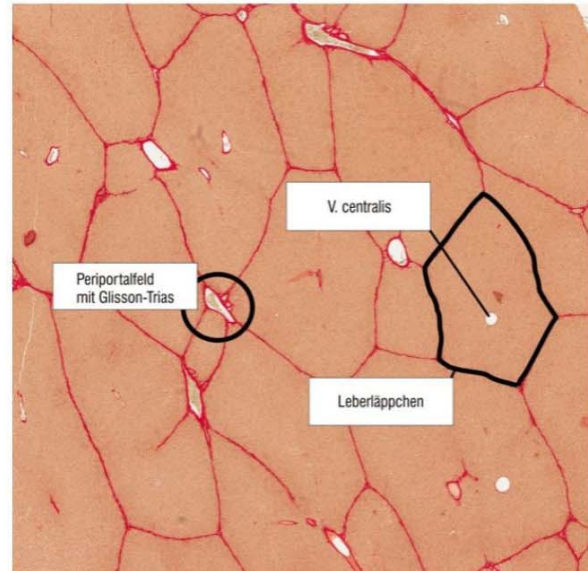


HISTOLOGIE WBT – © Christina Drees

Seite 3 von 14



Leber (Schwein) – Aufbau des klassischen Leberläppchens
– van Gieson



Leber (Schwein) – van Gieson

Bitte ordnen Sie die Begriffe per Drag & Drop den entsprechenden Strukturen der Leber zu.

V. centralis

Periportalfeld mit
Glisson-Trias

Leberläppchen

Auswerten

Zurücksetzen

Lösung

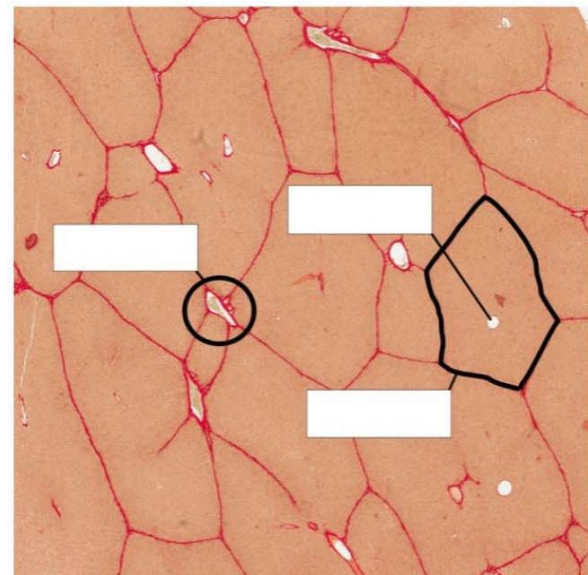


Figure 1.1: Exemplary design of the LU “Liver, gall bladder, pancreas”. A-C. The LU of the new software contains multimedia and interactive elements. Contents are presented in spoken form while the corresponding terms are displayed simultaneously. D. In every LU, the students have to answer a quiz question after each section. Students can review the acquired knowledge by means of the drag-and-drop question shown here.

Translation (German-English):

- Leber, Gallenblase Pankreas = Liver, gall bladder, pancreas
- Kapitel 1: Leber (Schwein) – van Gieson = Chapter 1: Liver (porcine) – van Gieson
- Leber (Schwein) – Aufbau des klassischen Leberläppchens – van Gieson = Liver (porcine) – Classical structure of hepatic lobules – van Gieson
- Leberläppchen = Hepatic lobule
- V. centralis = Central vein
- Periportalfeld mit Glisson-Trias = Periportal space with Glisson's triad
- Bitte ordnen Sie die Begriffe per Drag & Drop den entsprechenden Strukturen der Leber zu. = Please assign the designation to the respective structure by drag & drop.
- Auswerten = Assess
- Zurücksetzen = Reset
- Lösung = Solution